CHAPTER

74 The small intestine

Learning objectives

To appreciate:
- The basic anatomy and physiology of the small intestine
- The range of conditions that may affect the small intestine

To understand:
- The aetiology and pathology of common small intestinal conditions
- The principles of investigation of small intestinal symptoms
- The importance of non-surgical management of small intestinal problems
- The principles of small intestinal surgery
- That complex intestinal problems are best managed by a multidisciplinary team

ANATOMY OF THE SMALL INTESTINE

Although the duodenum is anatomically indistinguishable from the rest of the small intestine, in surgical terms it may be regarded as a distinct structure and is discussed in ***Chapter 67***. The small intestine lies between the duodenojejunal (DJ) flexure and the ileocaecal valve (***Figure 74.1***). It is difficult to establish the length of the small intestine. It varies widely between subjects (it is said to be longer in men) and estimates gathered at surgery, at postmortem and during radiological investigations have been noted to vary widely, even in the same individual. Most studies however describe a range between 300 and 850 cm.

The proximal 40% of the small intestine is referred to as the jejunum and the remainder is the ileum. There is no clear demarcation between jejunum and ileum, as the character of the small intestine changes gradually from proximal to distal. The jejunum tends to have a wider diameter and a thicker wall, with more prominent mucosal folds (valvulae conniventes), while the ileum has a thicker, more fatty mesentery with more complex arterial arcades. The ileum also contains larger aggregates of lymph nodes (Peyer's patches), which can occasionally become the lead points in childhood intussusception.

The small intestine has a rich blood supply, derived from the superior mesenteric artery (SMA), while venous drainage is via the portal venous system. The superior mesenteric vein joins the splenic vein to form the portal vein, which drains into the liver, carrying absorbed nutrients from the bowel for processing. The lymphatic drainage of the small intestine follows the arterial supply.

The small intestine has a rich autonomic innervation arising from the splanchnic nerves, which contribute a dense network of sympathetic fibres around the SMA and its branches. Referred pain from the small intestine is usually felt in the periumbilical region (T10). The blood and nerve supplies to the small intestine run in its mesentery, which is attached to the posterior abdominal wall and runs obliquely downwards to the right between the DJ flexure to the left of the second lumbar vertebra and the right sacroiliac joint (***Summary box 74.1***; see ***Chapter 65***).

Summary box 74.1

Important features of small bowel anatomy
- Comprises jejunum and ileum
- Has valvulae conniventes
- Blood supply from SMA

PHYSIOLOGY OF THE SMALL INTESTINE

The principal function of the small intestine is the digestion of food and absorption of nutrients, water and electrolytes. Carbohydrates and proteins are broken down in the intestinal lumen by pancreatic enzymes, but the final hydrolysis takes place at the brush border of the jejunum, after which these nutrients are absorbed. Fats are digested chiefly by the actions of pancreatic lipase and bile salts. The products of fat digestion, fatty acids and monoglycerides, separate from bile salts in the jejunum and are absorbed for further processing. The jejunum is the principal site for digestion and absorption of fluid, electrolytes, iron, folate, fat, protein and carbohydrate,

Valvulae conniventes describes a fold of mucous membrane that passes across two-thirds of the bowel circumference.
Johann Conrad Peyer, 1653–1712, Professor of Logic, Rhetoric and Medicine, Schaffhausen, Switzerland, described the lymph follicles in the intestine in 1677.

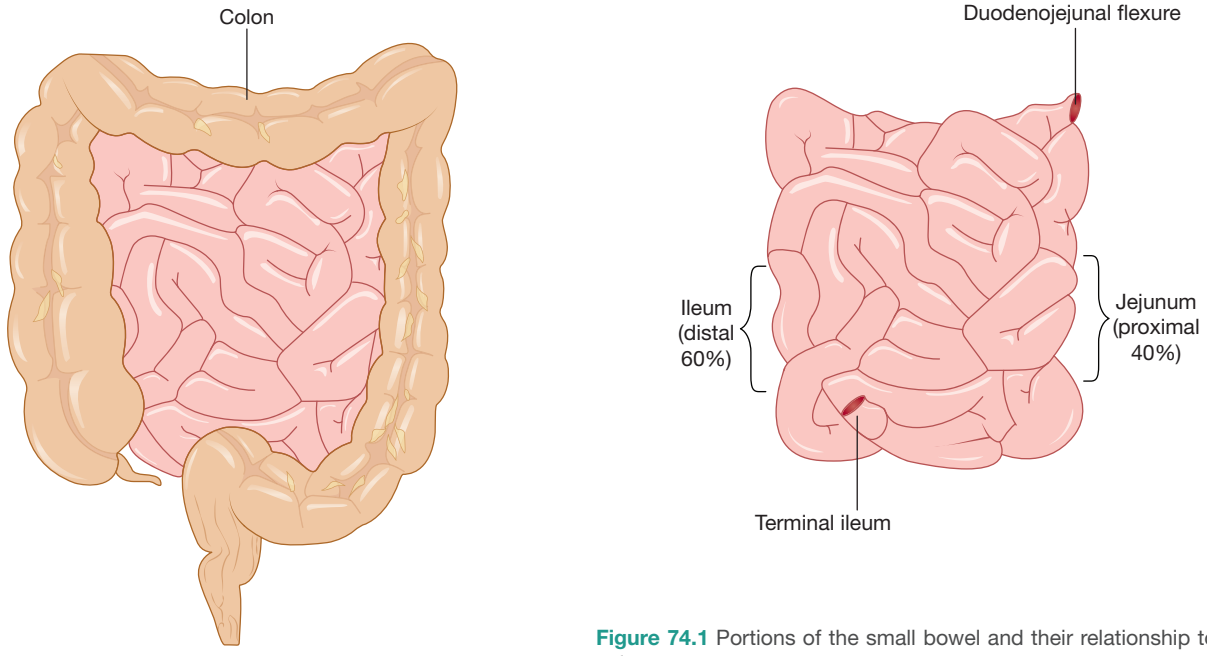

Figure 74.1 Portions of the small bowel and their relationship to the colon.

but the absorption of bile salts and vitamin B12 only occurs in the terminal ileum, where there are specific transporters. If the jejunum is resected, the ileum can assume all the required absorptive functions, but resection of the terminal ileum will result in a diminished bile salt pool, vitamin B12 deficiency and may lead to deficiency of the fat-soluble vitamins A, D, E and K. The ileum also plays an important role in water absorption, possibly because the tightness of the intercellular junctions supports a concentration gradient across its lumen. Significant ileal resection therefore commonly results in very troublesome diarrhoea.

The small intestine plays an important role in the metabolism of plasma lipoproteins, as it is the main site of synthesis of high-density, low-density and very low-density lipoproteins (HDL, LDL, VLDL). These particles transport most of the absorbed dietary fat to the systemic circulation via the lymph. The small bowel also synthesises intestinal hormones such as glucagon-like peptides GLP-1 and 2, peptide YY and motilin, which interact with the enteric nervous system to modulate intestinal function, growth and differentiation.

INFLAMMATORY BOWEL DISEASE

The term 'inflammatory bowel disease' is reserved for conditions characterised by the presence of idiopathic intestinal inflammation; conditions such as infective or ischaemic enteritis are, by definition, excluded. Crohn's disease (CD) is the only known 'inflammatory bowel disease' that affects the small intestine and is covered in detail in ***Chapter 75***.

INFECTIVE ENTERITIS

Campylobacter

Infection with *Campylobacter jejuni* (a Gram-negative rod with a distinctive spiral shape) is the most common form of bacterial gastroenteritis in the UK, typically acquired from eating infected poultry. It causes diarrhoea and abdominal pain and may mimic an acute abdomen. Severe cases may resemble ulcerative colitis, with rectal bleeding and colorectal ulceration, causing diagnostic difficulty. The organism is fastidious in culture and may take several days to isolate in the laboratory. Toxic dilatation and even disintegrative colitis have rarely been reported to occur. Treatment is generally supportive as the condition usually resolves without antibiotics. It is a notifiable disease.

Yersinia

Yersinia enterocolitica is a Gram-negative rod that can infect the terminal ileum, appendix, ascending colon and mesenteric lymph nodes, and can cause a granulomatous inflammatory process that may mimic CD. *Yersinia* typically causes a fever and gastroenteritis, but may persist and cause a terminal ileitis, which, on occasion, may perforate. The diagnosis may be made on stool culture, but is more often confirmed serologically. If discovered at laparotomy, the terminal ileum and mesenteric nodes will look thickened and inflamed and a lymph node biopsy can be taken for diagnostic purposes. The disease is normally self-limiting, but responds to treatment with co-trimoxazole or chloramphenicol antibiotics.

Burrill Bernard Crohn, 1884–1983, gastroenterologist, Mount Sinai Hospital, New York, NY, USA, along with Leon Ginzburg and Gordon Oppenheimer, described regional ileitis in 1932.

Salmonella, typhoid and paratyphoid

Salmonella are a family of Gram-negative rods that can cause a range of enteric infections. *Salmonella* gastroenteritis is typically caused by *Salmonella enteritidis* from poultry and is most often a self-limiting illness comprising headache, fever and watery diarrhoea. When severe, antibiotics and hospitalisation and intravenous fluids may be needed. The diagnosis is based on stool culture. *Shigella* and enteropathogenic strains of *Escherichia coli* may cause similar diarrhoeal illnesses.

Typhoid fever is caused by *Salmonella enterica* and presents with fever and abdominal pain after an incubation period of 10–20 days. Over the next week, the patient can develop distension, diarrhoea, splenomegaly and characteristic 'rose spots' on the abdomen caused by a vasculitis. Typhoid is a systemic infection and diagnosis of typhoid is confirmed by culture of blood or stool. Treatment is by antibiotics, usually chloramphenicol. A number of surgical complications can result, including paralytic ileus, intestinal haemorrhage, free ileal perforation and cholecystitis.

Invasion of the systemic circulation, which is a characteristic feature of salmonellosis, may cause severe Gram-negative sepsis, resulting in septic shock. Some patients develop metastatic sepsis, including septic arthritis and osteomyelitis, meningitis, encephalitis, disseminated intravascular coagulation and pancreatitis.

Perforation of a typhoid ulcer characteristically occurs during the third week of the illness, although it is sometimes the first clinical sign of the disease. The ulcer is parallel to the long axis of the gut and is usually situated in the distal ileum. Perforation requires surgery to wash out and close the ulcer and intestinal resection is usually avoided. In unstable patients, notably with evidence of septic shock, the bowel should be exteriorised and the perforation closed after recovery. Paratyphoid infection (with *Salmonella* Paratyphi A) resembles typhoid fever and is treated in a similar manner (see ***Chapter 6***).

Tuberculosis of the intestine

Tuberculosis, like CD, can affect any part of the gastrointestinal tract. The sites affected most often are the ileum, proximal colon and peritoneum. There are two principal disease presentations.

Ulcerative tuberculosis

Ulcerative tuberculosis develops secondary to pulmonary tuberculosis and arises as a result of swallowing tubercle bacilli. Multiple ulcers, lying transversely, develop in the terminal ileum and the overlying serosa is thickened, reddened and covered in tubercles. Patients typically present with diarrhoea and weight loss, although subacute obstruction and even local perforation and fistula formation can occur. A barium follow-through or computed tomography (CT) examination fails to show filling of the distal ileum, caecum and the ascending colon as a result of narrowing of the ulcerated segment (***Figure 74.2***).

A course of antituberculous chemotherapy usually leads to cure, provided the pulmonary tuberculosis is adequately treated. Surgery is usually undertaken only in the rare event of a perforation or complete intestinal obstruction.

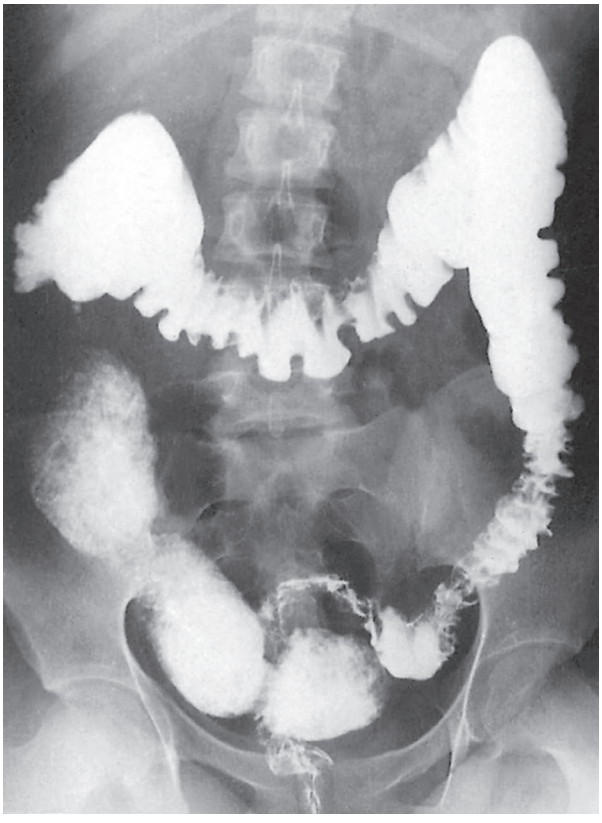

Figure 74.2 Ileocaecal tuberculosis showing dilatation of the distal ileum and stricturing of the terminal ileum and caecum (courtesy of Dr. VK Kapoor, Delhi, India).

Hyperplastic tuberculosis

This is caused by the ingestion of *Mycobacterium tuberculosis* by patients with a high resistance to the organism. The infection usually occurs in the ileocaecal region, although solitary and multiple lesions in the distal ileum are also sometimes seen. The infection establishes itself in lymphoid follicles, and the resulting chronic inflammation causes thickening of the intestinal wall and narrowing of the lumen. There is early involvement of the regional lymph nodes, which may caseate. Unlike in CD, abscess and fistula formation are uncommon.

Patients usually present with attacks of abdominal pain and intermittent diarrhoea. There is incomplete ileal obstruction, leading to stasis and bacterial overgrowth. This in turn causes steatorrhoea, anaemia and loss of weight. Patients may present with a mass in the right iliac fossa and vague ill health. The differential diagnosis is that of an appendix mass, lymphoma, carcinoma of the caecum, CD, tuberculosis or actinomycosis. A barium follow-through or small bowel enema will show a long narrow filling defect in the terminal ileum (which may result in a differential diagnosis of CD). CT will also demonstrate the narrowed segment with proximal distension and the associated lymphadenopathy. When the diagnosis is clear and the patient has not yet developed obstructive symptoms, treatment with antituberculous medication is advised and may be curative. Where obstruction is present, or the possibility of CD or lymphoma requires clarification, ileocaecal resection is often required (see ***Chapters 6 and 65***).

Actinomycosis

Abdominal actinomycosis is rare. It is caused by infection with *Actinomyces israelii* and usually develops several weeks after an apparently straightforward perforated appendicitis. An abscess develops and spreads to the retroperitoneal tissues and the adjacent abdominal wall, eventually becoming the seat of multiple indurated discharging sinuses. At first, the discharge from the sinuses is thin, watery and inoffensive, but it may later become thicker and malodorous. Secondary fistulation may occur and the tissues may become extensively indurated and woody. In contrast to tuberculosis, however, mesenteric lymph nodes are not involved and the lumen of the intestine is not narrowed. Haematogenous spread via the portal vein may lead to multiple liver abscesses.

Pus should be sent for bacteriological examination, which will reveal the characteristic sulphur granules. Penicillin or co-trimoxazole treatment is required and should be prolonged and in high dosage.

Human immunodeficiency virus

Human immunodeficiency virus (HIV) infection is associated with a number of proctological problems (see ***Chapter 80***). Intestinal complications are common after the development of acquired immunodeficiency syndrome (AIDS), when opportunistic organisms can cause gastroenteritis (***Summary box 74.2***). HIV may also cause a specific enteropathy. Treatment is directed towards the relevant organism and surgery should be avoided if possible.

Summary box 74.2

Opportunistic intestinal infections in patients with AIDS

- Bacterial
  - *Salmonella*
  - *Shigella*
  - *Yersinia*
  - *Campylobacter*
  - *Mycobacterium avium–intracellulare* (MAI)
- Viral
  - *Cytomegalovirus*
- Protozoal
  - *Cryptosporidium*
  - *Giardia*
- Fungal
  - *Candida albicans*

TUMOURS OF THE SMALL INTESTINE

Small bowel tumours are rare and in total account for less than 10% of gastrointestinal neoplasia.

Benign

The majority of small bowel neoplasms are benign, comprising adenomas, lipomas, haemangiomas and neurogenic tumours. They are frequently asymptomatic and identified incidentally, but can present with intussusception, small bowel obstruction and bleeding that may cause anaemia or may even be overt. Where these lesions do cause anaemia, the cause can be difficult to diagnose, as CT or small bowel contrast studies do not show them easily. Capsule endoscopy or small bowel endoscopy have been used successfully where the facilities exist. Symptomatic lesions can be treated by small bowel resection.

Figure 74.3 Melanin spots on the lips of a patient with Peutz–Jeghers syndrome (courtesy of Major PCM Manta, Indian Medical Service).

Peutz-Jeghers syndrome

This is an autosomal dominant condition characterised by melanosis of the mouth and lips, with multiple hamartomatous (benign tumour-like malformations resulting from faulty development in an organ) polyps in the small bowel and colon (***Figure 74.3***). Melanin spots can also occur on the digits and perianal skin. Mutation of the *STK11* gene on chromosome 19 has been found in a proportion of patients. Long-term follow-up of the original family described by Peutz has shown reduced survival as a consequence of complications of bowel obstruction and the development of a range of cancers. Regular colonic surveillance should be performed and female patients should attend breast and cervical screening. Despite the increased risk of malignancy in general, malignant change in the polyps themselves is uncommon. Resection may be indicated, however, for heavy and persistent or recurrent bleeding or intussusception. Polyps may be removed by enterotomy or, at laparotomy, snared via a colonoscope introduced via an enterotomy. Heavily involved segments of small intestine may occasionally be resected.

James Israel, 1848–1926, first found sulphur granules in pus from a discharging sinus in a man's neck. Later, he became a famous Berlin urologist.
John Law Augustine Peutz, 1886–1968, Chief Specialist for Internal Medicine, St. John's Hospital, The Hague, The Netherlands.
Harold Joseph Jeghers, 1904–1990, Professor of Internal Medicine, The New Jersey College of Medicine and Dentistry, Jersey City, NJ, USA.

Malignant

Small bowel malignancy is rare, classically presents late and is most often diagnosed after surgery for small bowel obstruction. Four types will be considered, which account for over 99% of small bowel malignancies: adenocarcinoma, neuroendocrine tumours (NETs), lymphomas and gastrointestinal stromal tumours (GISTs).

Adenocarcinoma

Small bowel adenocarcinoma is more often found in the jejunum than in the ileum and, although the aetiology is unknown, it is more common in patients with CD, coeliac disease, familial adenomatous polyposis, hereditary non-polyposis colon cancer and Peutz–Jeghers syndrome. The tumours present with anaemia, overt gastrointestinal bleeding, intussusception or obstruction. Prognosis is poor, particularly in patients with CD, in whom these tumours often present late because the symptoms are commonly mistaken for those of CD and treated conservatively. When diagnosed, surgical treatment is a resection of 5 cm of non-involved bowel either side of the lesion and the affected mesentery (***Figure 74.4***). A right hemicolectomy is likely to be required for tumours of the distal ileum.

Neuroendocrine tumours

NETs (previously known as carcinoid tumours) occur throughout the gastrointestinal tract, most commonly in the appendix, ileum and rectum in decreasing order of frequency. They arise from Kulchitsky cells at the base of intestinal crypts (of Lieberkuhn). The primary is usually small, although significant lymph node metastases can occur. In up to one-third of cases of small bowel NETs, the tumours are multiple. They may produce dense fibrosis in the surrounding tissues, resulting in distortion and scarring of the bowel and associated mesentery, giving them a characteristic radiological appearance. NETs can produce a number of vasoactive peptides, most commonly 5-hydroxytryptamine (serotonin), but also histamine, prostaglandins and kallikrein. When they metastasise to the liver, the 'carcinoid syndrome' can become evident because the vasoactive substances escape the filtering actions of the liver. The clinical syndrome itself consists of reddish-blue cyanosis, flushing attacks, diarrhoea, borborygmi, asthmatic attacks and, eventually, pulmonary and tricuspid stenosis (***Summary box 74.3***). Classically, the flushing attacks are induced by alcohol.

Surgical resection is usually sufficient for patients with primary disease, but the incidence of recurrence is significant.

Summary box 74.3

Carcinoid syndrome

- Diarrhoea
- Bronchospasm
- Facial/upper chest flushing
- Palpitations
- Tricuspid regurgitation

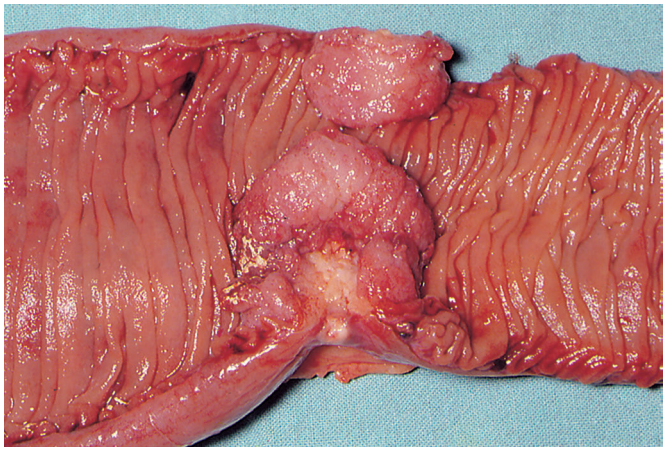

Figure 74.4 Small bowel adenocarcinoma.

The extent of disease can be assessed preoperatively using octreotide scanning (somatostatin receptor scintigraphy), which may detect otherwise clinically unapparent primary and secondary tumours. Plasma markers of tumour bulk, such as chromogranin A concentrations, may be useful markers of disease recurrence, as well as of prognostic value.

Hepatic resection can be carried out in patients with metastatic disease. The treatment has been transformed by the use of octreotide (a somatostatin analogue), which reduces both flushing and diarrhoea, and octreotide cover is usually used in patients with a carcinoid syndrome who have surgery to prevent a carcinoid crisis resulting from liberation of vasoactive substances following handling of the tumour. NETs generally grow more slowly than most metastatic malignancies and patients may live with metastatic disease for many years. The tumour is not usually sensitive to chemo- or radiotherapy (see ***Chapter 69***).

Lymphoma

Small bowel lymphoma may be primary or, more commonly, secondary to systemic lymphoma. The incidence of small bowel lymphoma is increased in patients with CD and immunodeficiency syndromes. The classification of lymphoma is beyond the scope of this chapter but a number of points are worth noting briefly. It is rare for Hodgkin's lymphoma to affect the small bowel and most Western-type lymphomas are non-Hodgkin's B-cell lymphomas. They usually present with anaemia, bleeding, perforation, anorexia and weight loss.

Small bowel T-cell lymphoma can develop in patients with coeliac disease. It usually presents with worsening of the patient's diarrhoea, pyrexia of unknown origin and local obstructive symptoms. Mediterranean lymphoma is found mostly in North Africa and the Middle East and is often widespread at diagnosis. Burkitt's lymphoma can aggressively affect the ileocaecal region, particularly in children. The mainstay of treatment for these conditions is chemotherapy; however, surgery may be required for obstruction, perforation or bleeding.

Nikolai Kulchitsky, 1856–1925, Professor of Histology, Kharkov, Ukraine, who left Russia after the Revolution of 1917 and later worked at University College, London, UK. He described these cells in 1897.
Johann Nathaniel Lieberkühn, 1711–1756, physician and anatomist, Berlin, Germany, described these glands in 1745.
Thomas Hodgkin, 1798–1866, lecturer in morbid anatomy and curator of the museum, Guy's Hospital, London, UK, described lymphadenoma in 1832.
Denis Parsons Burkitt, 1911–1993, Irish-born surgeon who worked in Kampala, Uganda.

Gastrointestinal stromal tumours

GISTs are mesenchymal tumours and the distinction between benign and malignant types is difficult even on histological examination. Increased size and high levels of *c-kit* (CD117) staining are associated with malignant potential. GISTs are found most commonly in the stomach but can be found in other parts of the gut. They occur most commonly in the 50- to 70-year age group. Although the cause is unknown, patients with neurofibromatosis have an increased risk of developing these types of tumour. Patients may be asymptomatic and the tumour may present as an incidental mass on a CT scan. Symptoms include lethargy, pain, nausea, haematemesis or melaena. Surgery is the most effective way of treating GISTs as the tumour is radioresistant and is not sensitive to conventional chemotherapy. Imatinib is a tyrosine kinase inhibitor that has been shown to be effective in advanced cases and may also have a role in adjuvant treatment. It may be used preoperatively to reduce tumour size; however, the involuting tumour may perforate, precipitating a surgical crisis (see ***Chapters 11 and 67***).

CONNECTIVE TISSUE DISORDERS

Intestinal diverticula

Diverticula (hollow outpouchings) are a common structural abnormality that can occur from the oesophagus to the rectosigmoid junction. Small bowel diverticula may be congenital or acquired. In congenital diverticula all three coats of the bowel are present in the wall of the diverticulum (e.g. Meckel's diverticulum).

Acquired diverticula

These often develop in the jejunum and arise from the mesenteric side of the bowel as a result of mucosal herniation at the point of entry of the blood vessels, where there is a potential defect in the muscularis layer. Jejunal diverticula can vary in size and are frequently multiple. They are commonly asymptomatic and present as an incidental finding at surgery or on radiological imaging. However, they can result in malabsorption, due to bacterial overgrowth, or present as an acute abdominal emergency if they become inflamed or perforate. Bleeding from a jejunal diverticulum is a rare complication (compared with sigmoid diverticular disease). Elective resection of an affected small bowel segment causing malabsorption can be effective, provided there is only a limited amount of jejunum involved. If perforated jejunal diverticulitis is found at emergency laparotomy, a small bowel resection should be performed and a decision made between primary anastomosis and stoma formation. This will depend on the degree of contamination, physiological stability and local resources for managing a patient with a high-output jejunostomy.

Complications resulting from extensive jejunal diverticulosis can be extremely difficult to treat. In severe cases, much of the proximal small intestine may be involved, effectively precluding resection. Prolonged antibiotic therapy for bacterial overgrowth may be preferable, and antibiotics (metronidazole, ciprofloxacin, rifaximin) may be rotated in an attempt to avoid antibiotic resistance. Limited resection, leaving remaining segments of affected jejunum, may be feasible, but may also fail to deal adequately with bacterial overgrowth, recurrent attacks of inflammation or bleeding.

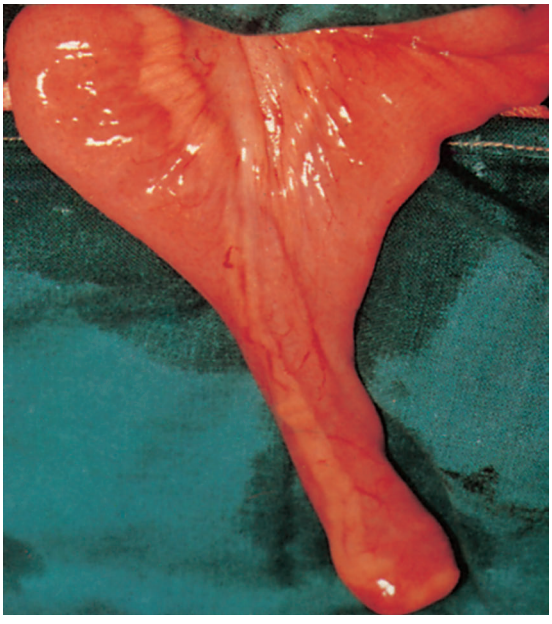

Figure 74.5 Meckel's diverticulum.

Meckel's diverticulum

A Meckel's diverticulum is a persistent remnant of the vitellointestinal duct and is present in about 2% of the population. It is found on the antimesenteric side of the ileum approximately 60 cm from the ileocaecal valve and is classically 5 cm long (2% prevalence; 2 feet [60 cm] from ileocaecal valve; 2 inches [5 cm] long). A Meckel's diverticulum is a congenital diverticulum (***Figure 74.5***). It contains all three coats of the bowel wall and has its own blood supply. It may be vulnerable to obstruction and inflammation in the same way as the appendix; indeed, when a normal appendix is found at surgery for suspected appendicitis, a Meckel's diverticulum should be looked for by examining the small bowel, particularly if free fluid or pus is found (see ***Chapter 76***). In approximately 20% of cases, the mucosa of a Meckel's diverticulum contains heterotopic epithelium of gastric, colonic or pancreatic type. The presence of heterotopic mucosa may predispose to the development of complications (***Summary box 74.4***).

The vast majority of Meckel's diverticula are asymptomatic and a Meckel's diverticulum is notoriously difficult to visualise with contrast radiology. Meckel's diverticulum may however present clinically in the following ways.

Haemorrhage. If gastric mucosa is present, peptic ulceration can occur and present as painless dark rectal bleeding or melaena. If the stomach, duodenum and colon are excluded as a source of bleeding by endoscopy, radioisotope scanning with technetium-99m may demonstrate a Meckel's diverticulum.

Johann Friedrich Meckel (the younger), 1781–1833, Professor of Anatomy and Surgery, Halle, Germany, described the diverticulum in 1809.

Diverticulitis. Meckel's diverticulitis presents like appendicitis, although if perforation occurs the presentation may resemble a perforated duodenal ulcer.

Intussusception. A Meckel's diverticulum can be the lead point for ileoileal or ileocolic intussusception.

Chronic ulceration. Pain is felt around the umbilicus, as the site of the diverticulum is midgut in origin.

Intestinal obstruction. A band between the apex of the diverticulum and the umbilicus (also part of the vitello-intestinal duct) may cause obstruction directly, or by predisposing to the development of a volvulus around it.

Perforation. (*Figure 74.6*).

When found in the course of abdominal surgery, a Meckel's diverticulum can safely be left alone, provided it has a wide mouth and is not thickened. When there is doubt, it can be resected. The finding of a Meckel's diverticulum in an inguinal or femoral hernia has been described as 'Littre's hernia'.

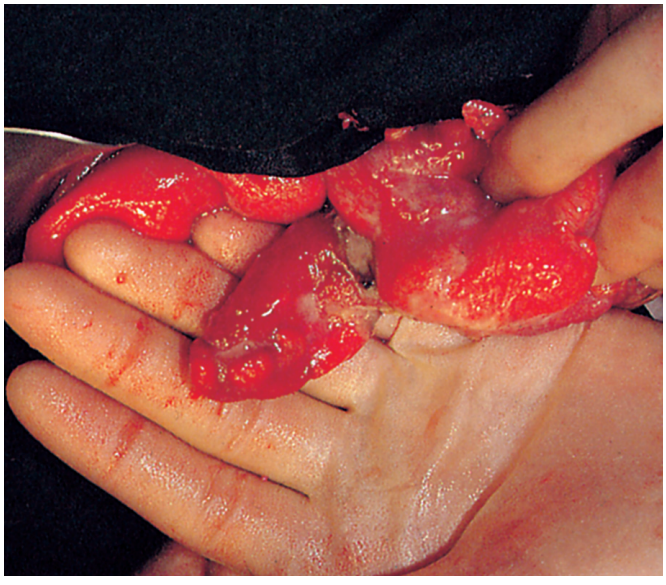

Figure 74.6 Gangrenous Meckel's diverticulitis.

Summary box 74.4

Features of Meckel's diverticulum

- Remnant of vitellointestinal duct
- Occurs in 2% of patients, 5 cm (2 inches) long, 60 cm (2 feet) from the ileocaecal valve, 20% heterotopic epithelium
- Should be looked for when a normal appendix is found at surgery for suspected appendicitis
- If a Meckel's diverticulum is found incidentally at surgery, it can be left provided it has a wide mouth and is not thickened
- Can be a source of gastrointestinal bleeding if it contains ectopic gastric mucosa

Meckel's diverticulectomy

A broad-based Meckel's diverticulum should not be amputated at its base and invaginated (as for an appendix), as there is the risk of stricture and of leaving heterotopic epithelium behind. It is safer simply to excise the diverticulum, either by resecting the diverticulum and suturing the defect at its base or by performing a limited small bowel resection with anastomosis. This can also be achieved with a linear stapler–cutter. If the base of the diverticulum is indurated, it is on balance safer to perform a limited small bowel resection of the entire involved segment, followed by an anastomosis.

VASCULAR ANOMALIES OF THE INTESTINE

Mesenteric ischaemia

Mesenteric vascular disease may be classified as acute intestinal ischaemia – with or without occlusion – venous, chronic arterial, central or peripheral. The superior mesenteric vessels are the visceral vessels most likely to be affected by embolisation or thrombosis. Occlusion at the origin of the SMA is almost invariably the result of thrombosis, whereas emboli tend to lodge at the origin of the middle colic artery. Inferior mesenteric artery involvement is usually clinically silent because of a rich collateral circulation.

SMA emboli may be carried from the left atrium in atrial fibrillation, the left ventricle after mural myocardial infarction, vegetations on mitral and aortic valves associated with endocarditis or an atheromatous plaque from an aortic aneurysm. Primary thrombosis is associated with atherosclerosis and vasculitides, including conditions such as thromboangitis obliterans and polyarteritis nodosa. Primary thrombosis of the superior mesenteric veins may occur in association with factor V Leiden disorder, portal hypertension, portal pyaemia, sickle cell disease and in women taking the oral contraceptive pill. A specific form of 'non-occlusive mesenteric ischaemia' (in which the vessels are normal but flow is critically reduced) may complicate critical illness, possibly because of alterations in splanchnic blood flow.

Irrespective of whether the occlusion is arterial or venous, haemorrhagic infarction occurs. The mucosa is especially sensitive to ischaemic injury because of its high metabolic activity. The intestine and its mesentery become swollen and oedematous, especially with venous occlusion. Bloodstained fluid exudes into the peritoneal cavity and bowel lumen. The changes develop rapidly and irreversible injury, ranging in severity from mucosal necrosis and sloughing to full-thickness infarction, usually occurs within 6 hours at most. If the main trunk of the SMA is involved, the infarction usually covers an area from just distal to the DJ flexure to the splenic flexure. Usually, a branch of the main trunk is implicated and the area of infarction is smaller.

Clinical features

The most important clue to an early diagnosis of acute mesenteric ischaemia is sudden onset of severe abdominal pain in a

Alexis Littre, 1658–1746, surgeon and Lecturer in Anatomy, Paris, France, described Meckel's diverticulum in a hernial sac in 1700, 81 years before Meckel was born.

patient with atrial fibrillation or atherosclerosis. The pain is typically in the central abdomen and is out of all proportion to the physical findings. Persistent vomiting and defecation occur early, with the subsequent passage of altered blood. Abdominal tenderness may be mild initially, with rigidity being a late feature. Shock, with features of both hypovolaemia and sepsis, rapidly ensues.

Investigation

Investigation will usually reveal a profound neutrophil leukocytosis, a severe metabolic acidosis and raised blood lactate. A contrast-enhanced CT scan will show bowel wall enhancement absent or reduced and there may be free fluid in the abdomen. Gas may be present within the intestinal wall and occasionally in the mesenteric and portal vein, a late and ominous sign.

Treatment

Mesenteric venous thrombosis may be treated by anticoagulation with close monitoring. An immediate laparotomy with embolectomy or revascularisation of the SMA by vascular bypass may be considered in early cases of arterial ischaemia, followed by postoperative anticoagulation. However, the condition is usually diagnosed late in the disease process and the mortality rate is extremely high. In the young, all affected bowel should be resected, whereas in the elderly or infirm the situation may be deemed incurable. Where the demarcation between viable and non-viable bowel is uncertain a planned relook laparotomy may be useful.

After extensive enterectomy, it is usual for patients to require intravenous nutrition. The young, however, may sometimes develop sufficient intestinal digestive and absorptive function to lead relatively normal lives. In selected cases, consideration may be given to small bowel transplantation (see ***Chapter 91***).

Chronic small intestinal ischaemia

Chronic small intestinal ischaemia almost invariably results from atherosclerosis and affects the proximal superior mesenteric and coeliac vessels. Patients classically present with symptoms of severe central abdominal pain that comes on within 30–60 minutes of eating (mesenteric angina). Weight loss and diarrhoea due to malabsorption may also occur. The condition may be difficult to diagnose and is often overlooked. The presence of significant vascular disease on CT is common in elderly patients and in those with severe vascular disease and should not necessarily be assumed to indicate that abdominal symptoms are attributable to chronic ischaemia. Treatment is usually by selective visceral angiography, with stenting/angioplasty and, where this is not possible, bypass surgery. Smoking cessation is imperative and patients are usually anticoagulated.

STOMAS

A stoma is an artificial opening made in the bowel to divert faeces and flatus outside the abdomen, where they can be collected in an external appliance. Depending on the purpose for which the diversion has been necessary, a stoma may be temporary or permanent (***Summary box 74.5***).

Summary box 74.5

Stomas

- May be colostomy or ileostomy
- May be temporary or permanent
- Temporary or defunctioning stomas are usually fashioned as loop stomas
- An ileostomy is spouted; a colostomy is flush
- Ileostomy effluent is usually liquid, whereas colostomy effluent is usually solid
- Ileostomy patients are more likely to develop fluid and electrolyte problems
- An ileostomy is usually sited in the right iliac fossa
- End-colostomy is usually sited in the left iliac fossa
- Whenever possible, patients should be counselled and sited by a stoma care nurse before operation

Loop ileostomy

A loop ileostomy is often used for defunctioning a low rectal anastomosis or an ileal pouch. A knuckle of ileum is exteriorised through a skin trephine in the right iliac fossa. An incision is made in the distal part of the knuckle, and this is then pulled over the top of the more proximal part to create a spout on the proximal side of the loop with a flush distal side still in continuity. This allows near perfect defunctioning, but also the possibility of restoration of continuity, by taking down the spout and reanastomosing the partially divided ileum.

The advantage of a loop ileostomy over a loop colostomy is the ease with which the bowel can be brought to the surface. Care is needed when the ileostomy is closed such that suture line obstruction does not occur. Closure of a loop ileostomy can be a technically challenging procedure, particularly if there are dense adhesions resulting from previous surgery.

End-ileostomy

An end-ileostomy is formed after a colectomy without anastomosis, when it may later be reversed, or after panproctocolectomy, when it is permanent. The ileum is normally brought through the rectus abdominis muscle. Careful attention should be paid to the terminal ileal mesentery to ensure that it is not too bulky. The use of a spout was originally described by Brooke; this should project some 2–4 cm from the skin surface (***Figure 74.7***). A disposable appliance is placed over the ileostomy so that it is a snug fit at skin level.

There may be an 'ileostomy flux' while the ileum adapts to the loss of the colon. While ileostomy output can amount to 4–5 litres per day, losses of 1–2 litres are more common. A consistent ileostomy output in excess of 1.5 litres is usually associated with dehydration and sodium depletion in the absence of intravenous therapy. Up to 20% of patients may require readmission for the treatment of dehydration after creation of

Bryan Nicholas Brooke, 1915–1998, Professor of Surgery, St George's Hospital, London, UK.

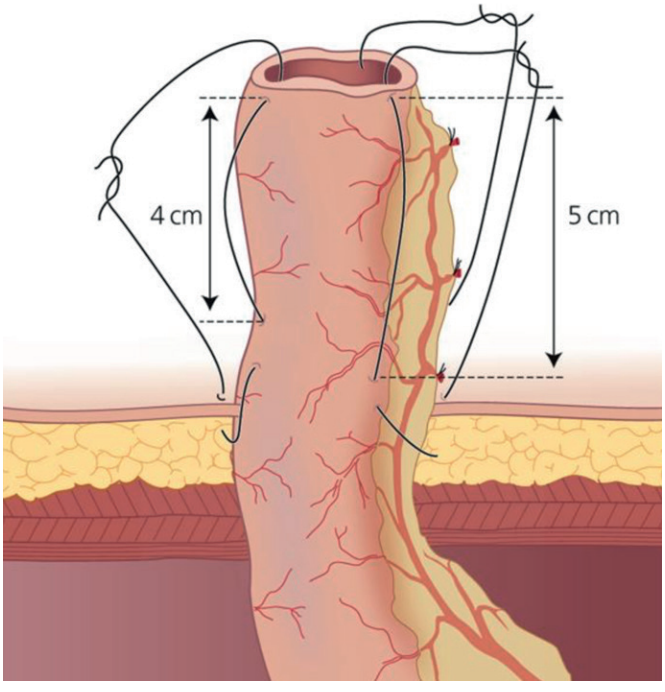

Figure 74.7 Construction of an end-ileostomy. The diagram is orientated such that the upper aspect of the stoma is to the right, thus when the sutures are tied the everted stoma is angled slightly inferiorly. (Reproduced with permission from O'Connell PR, Madoff RD, Solomon MJ (eds). *Operative surgery of the colon rectum and anus*, 6th edn. Boca Raton, FL: CRC Press, 2015.)

an ileostomy but the stools thicken in a few weeks and are usually semisolid in a few months. The help, skill and advice of the stoma care nurse specialist are essential. Modern appliances have transformed stoma care and skin problems are unusual (***Figure 74.8***). Complications of an ileostomy include prolapse, retraction, stenosis, bleeding, fistula and parastomal hernia.

Stoma bags and appliances

Stoma output is collected in a disposable adhesive bag. Ileostomy appliances tend to be drainable bags that are left in place for 48 hours, while colostomy appliances are simply changed two or three times each day. A wide range of such bags is currently available. Many now incorporate an adhesive backing, which can be left in place for several days. In most hospitals, a stoma care service is available to offer advice to patients, to acquaint them with the latest appliances and to provide the appropriate psychological and practical help.

Complications of stomas

Stoma complications are underestimated and common (***Summary box 74.6***). On occasion, these complications require surgical revision. Sometimes, this can be achieved with an incision immediately around the stoma, but on occasion reopening the abdomen and freeing up the stoma may be necessary. Repair of parastomal hernias is particularly technically challenging and the recurrence rate is high. Simple

Figure 74.8 Spouted ileostomy in the right iliac fossa.

suture of the parastomal hernia is associated with an almost 100% risk of recurrence and transfer to the opposite side of the abdomen, or insertion of a piece of prosthetic material within the abdominal wall around the stoma may be necessary (see ***Chapter 64***).

Summary box 74.6

Stoma complications

- Skin irritation
- Prolapse
- Retraction
- Ischaemia
- Stenosis
- Parastomal hernia
- Bleeding
- Fistulation

CONDITIONS CAUSING MALABSORPTION

Coeliac disease

Coeliac disease is the most common cause of malabsorption in the UK with a reported prevalence of 1:1800, although this may be an underestimate. It is characterised by a hypertrophic small bowel mucosa with atrophic villi and deep crypts. Loss of surface area and brush border enzymes results in malabsorption.

Coeliac disease is caused by an abnormal immune response to gluten, a cereal protein, although the exact mechanism remains unclear. There is a genetic component, as the disease is more common in first-degree relatives and has an association with HLA-B8. In children, coeliac disease presents with steatorrhoea and growth retardation. In adults, it may result in diarrhoea and weight loss but many patients simply present with iron deficiency anaemia. Some patients develop a characteristic skin rash (dermatitis herpetiformis).

The diagnosis is usually made after an endoscopic duodenal biopsy allows pathological examination of the mucosa. A blood test for immunoglobulin A anti-tissue transglutaminase (IgA tTGA) is relatively sensitive and specific for diagnosing coeliac disease, making it the preferred test for detection. Measurement of IgA antiendomysial antibodies (anti-EMA) should be used as a confirmatory test. A duodenal biopsy is usually indicated to confirm the diagnosis. The biopsy usually shows

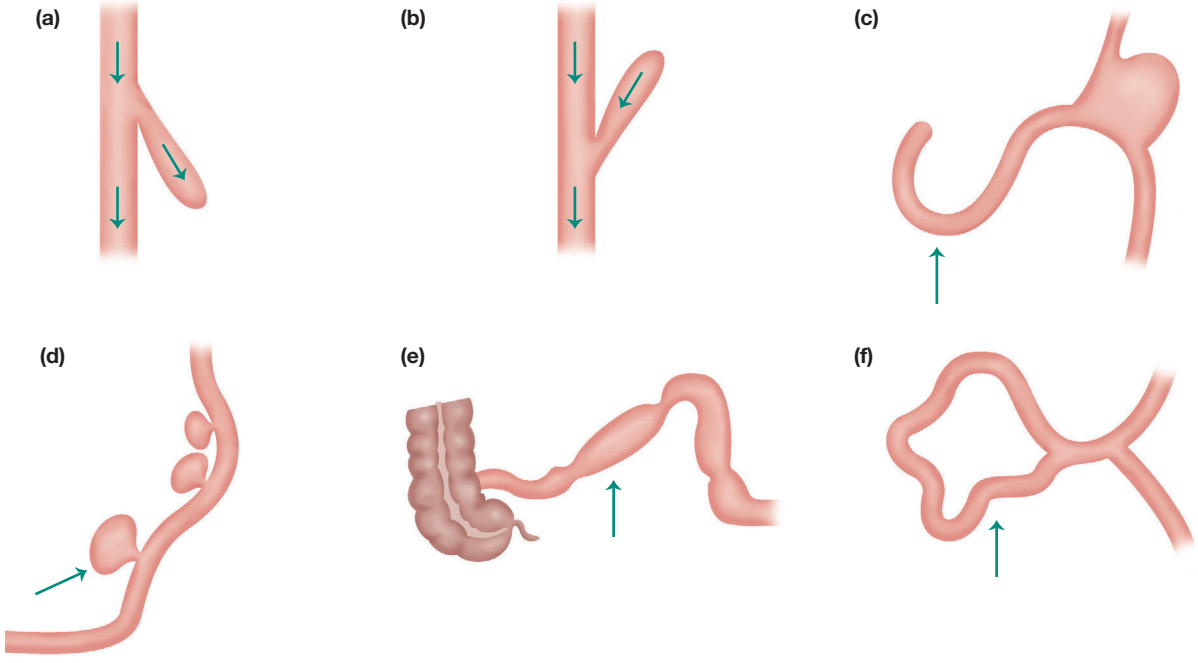

Figure 74.9 Common types of blind loop: **(a)** self-filling: deficiency occurs; **(b)** self-emptying: no deficiency occurs; **(c)** long afferent loop stasis in Pólya gastrectomy; **(d)** jejunal diverticula; **(e)** intestinal stricture causing stasis; **(f)** 'stenosis–anastomosis loop' syndrome.

flattening of the mucosa, marked inflammatory changes and characteristic findings of intraepithelial lymphocytes. All tests should be performed while the patient is on a gluten-containing diet as false-negative tests may occur if on a gluten-free diet.

Patients with coeliac disease may develop an acute inflammatory condition of the small intestine (ulcerative jejunoileitis) and have an increased risk of small bowel lymphoma and adenocarcinoma.

The main treatment for coeliac disease is the withdrawal of gluten from the diet by avoiding wheat, rye and barley. Surgery does not usually play a role in the management of coeliac disease and is primarily reserved for resection of malignancy.

Bacterial overgrowth

The small intestine can become colonised with bacteria normally confined to the colon if there is stasis resulting in delayed bacterial clearance (blind loop syndrome; ***Figure 74.9***). Similar complications may result from chronic small bowel obstruction, jejunal diverticulosis and ileocolic fistulation. Overgrowth in the upper small intestine results in fat malabsorption due to the deconjugation of bile salts, while vitamin B12 deficiency results from overgrowth more distally. There is usually relatively little effect on carbohydrate or protein metabolism. If steatorrhoea occurs, other serious malabsorption features may follow, including glossitis, osteomalacia, paraesthesia and peripheral neuropathy.

Improvement normally follows after intermittent therapy with oral antibiotics; metronidazole, ciprofloxacin, tetracycline and rifaximin are commonly used. Definitive treatment is surgical if the anatomical abnormality can be corrected, but this is not always possible.

ENTEROCUTANEOUS FISTULA

An abnormal connection between the small intestine and the skin can occur as a result of CD, radiotherapy or abdominal trauma, but the condition most commonly follows a surgical complication – either a leak from an anastomosis or an inadvertent enterotomy. At least 50% of small bowel enterocutaneous fistulae develop after surgery in which no small bowel has been resected as a result of injury to the intestine during division of adhesions. The frequency of this complication has been shown to increase with the number of previous laparotomies. Management of patients with an enterocutaneous fistula can be very challenging, especially when the fistula output is high (defined as >500 mL of effluent/day). The majority of low-output fistulae can be expected to heal spontaneously, provided there is no distal obstruction or disease at the fistula site. Reasons for failure of spontaneous healing also include epithelial continuity between the gut and the skin and an associated complex abscess.

The management of fistulae is based on well-established principles ('SNAP'; see ***Summary box 74.7***). An early return to theatre to try to treat the problem definitively (i.e. by

Eugen (Jeno) Alexander Pólya, 1876–1944, surgeon, St Stephen's Hospital, Budapest, Hungary.

attempting to restore bowel continuity) in a septic, malnourished patient is doomed to failure.

Summary box 74.7

Principles of management of enterocutaneous fistulae (SNAP)

- S, elimination of Sepsis and skin protection
- N, Nutrition – a period of parenteral nutrition may well be required
- A, Anatomical assessment
- P, definitive Planned surgery

Infected collections are best identified at CT (***Figure 74.10***) and can be drained percutaneously. Skin protection is important as small bowel effluent is caustic. Nutritional support must include fluid and electrolytes, which can be lost in high quantities from a proximal fistula, as well as carbohydrates, protein, fat and vitamins. Judgements have to be made between enteral and parenteral feeding: enteral feeding has advantages, but if the fistula is proximal or high output total parenteral nutrition will be required. Defining fistula anatomy is best done after careful discussion with the radiologist; a sequence of contrast studies (follow-through, fistulogram and enema) may well be required to define bowel length and plan a surgical strategy. Surgery can be extremely technically demanding and an anastomosis should be avoided in the presence of continuing intra-abdominal sepsis or when the patient is hypoalbuminaemic (<32 g/dL).

SHORT BOWEL SYNDROME/ INTESTINAL FAILURE

Intractable diarrhoea with impaired absorption of nutrients following resection or bypass of the small intestine, ultimately leading to progressive malnutrition, is referred to as short bowel syndrome. When a patient is unable to maintain satisfactory fluid, electrolyte or nutritional homeostasis without intravenous administration of fluid, electrolytes or nutrients they are said to have intestinal failure. The mainstay of treatment for intestinal failure is parenteral nutrition.

The most common causes of short bowel syndrome are resection resulting from the management of CD and its complications (which accounts for almost half of cases), mesenteric vascular thrombosis, radiation enteritis and tumours. Although features of short bowel syndrome usually appear when there is less than 200 cm of small bowel, the length and nature of the remaining intestine are also important. In general, diseases that result in short bowel syndrome tend to preferentially affect the distal small intestine, and there is some evidence that the ileum, with its tighter intercellular junctions and consequently better fluid absorptive capacity, can assume the functions of a missing jejunum, but not *vice versa*. While the ileocaecal valve used to be considered important with regard to preservation of absorptive function, it is more likely that this is a reflection of the associated preservation of the distal ileum and right colon than the valve itself.

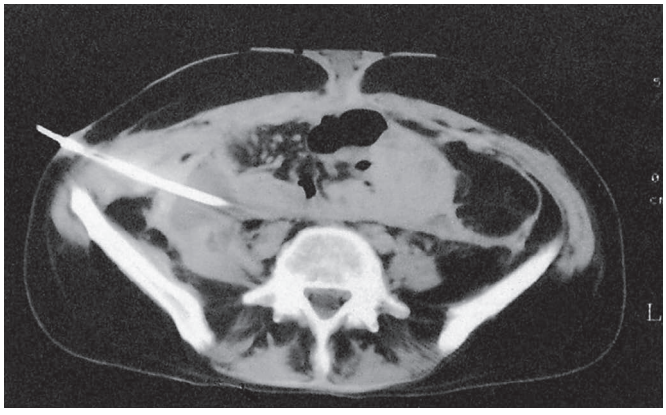

Figure 74.10 Computed tomography (CT) scan in a patient with a complex enterocutaneous fistula and an intra-abdominal abscess being drained with a CT-guided catheter.

Patients with an intact colon are relatively protected from the effects of massive small bowel resection because of the ability of the colon to absorb not only fluid and electrolytes but also a modest amount of nutrient energy. Patients with as little as 100–200 cm of jejunum anastomosed to an intact colon may therefore be able to maintain satisfactory macronutrient, fluid and electrolyte status, although they will, of course, be at risk of fat-soluble and B12 vitamin deficiencies and will also generally need oral nutritional supplements of trace elements, vitamins and minerals. Some (but not all) patients with 50–100 cm of small intestine and an intact colon will have intestinal failure, as will almost all patients with 50 cm or less of jejunum anastomosed to an intact colon. In contrast, most patients with less than 200 cm and virtually all with less than 100 cm of small intestine ending in a stoma will have intestinal failure and will require long-term parenteral nutrition.

Medical management of patients with short bowel syndrome relies on the use of antidiarrhoeal agents (loperamide and codeine phosphate), drugs to reduce diarrhoea related to bile-salt malabsorption (cholestyramine), drugs to reduce the increased gastric acid secretion resulting from the loss of the small bowel 'brake' on gastric acid production (proton pump inhibitors) and enteral and parenteral vitamin and trace element supplements. Although there has also been interest in the use of drugs to promote intestinal adaptation, such as growth hormone, glutamine and, most recently, glucagon-like peptide 2 agonists, the mainstay of treatment for short bowel syndrome remains home parenteral nutrition (HPN). The development of this treatment in the late 1960s enabled the majority of patients with short bowel syndrome to enjoy a reasonably good quality of life, with long-term survival related principally to the underlying disease. HPN is, however, expensive and demanding and patients are at risk from catheter-related complications (notably catheter-related sepsis and occlusion), as well as metabolic complications (fibrotic liver disease, gallstones, metabolic bone disease and kidney stones).

Surgical procedures designed to improve the surface area or reduce the speed of transit of the remaining small intestine (and thus improve absorptive capacity) have shown some promise in children, but their place in managing adults with

established short bowel syndrome currently remains unclear. In some patients, the loss of venous access resulting from the complications of long-term intravenous feeding or the development of progressive liver dysfunction may represent indications for small bowel transplantation. The results of small bowel transplantation have progressively improved and 5-year patient survival now exceeds 80% in some centres (see ***Chapter 91***).

FURTHER READING

Bland KI, Sarr MG, Büchler MW *et al.* (eds.) *Surgery of the small bowel*. Handbooks in General Surgery. London: Springer-Verlag, 2011.

Keighley MRB, Williams NS. *Keighley & Williams' surgery of the anus rectum and colon*, 4th edn. Boca Raton, FL: CRC Press, 2018.

Slade DAJ, Carlson GL. Takedown of enterocutaneous fistula and complex abdominal wall reconstruction. *Surg Clin North Am* 2013; **93**: 1163–83.

Soop M, Carlson GL. Intestinal failure: In: Herold A, Lehur P-A, Matzel KE, O'Connell PR (eds). *European manual of medicine: coloproctology*, 2nd edn. Berlin: Springer, 2017.